

Company Name

Name: Fname Lname
Chart #: /SharedID
DOB: /DOB
Age: /Age
Date: /Today

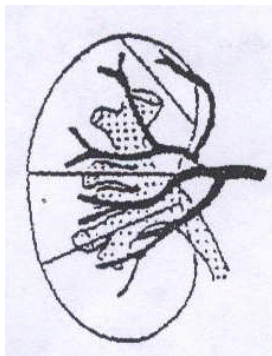
RENAL ULTRASOUND (PBUARE)

Sex: M / F

REASON FOR EXAM: _____

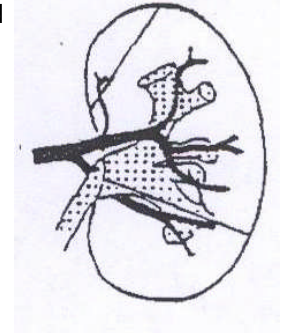
RIGHT KIDNEY: ____ cm X ____ cm X ____ cm

- Echogenicity: NML / Hyper / Hypo
- Continuous renal sinus: Y / N
- Cortex: WNL / Thick / Thin
- Contour: Smooth / Lobulated
- Y / N Column of bertin
- Y / N Pyramids ident
- Y / N Hydronephrosis
- Y / N Echogenic foci
- Y / N Cystic structure
- Y / N Solid mass
- Y / N Complex mass



LEFT KIDNEY: ____ cm X ____ cm X ____ cm

- Echogenicity: NML / Hyper / Hypo
- Continuous renal sinus: Y / N
- Cortex: WNL / Thick / Thin
- Contour: Smooth / Lobulated
- Y / N Column of bertin
- Y / N Pyramids ident
- Y / N Hydronephrosis
- Y / N Echogenic foci
- Y / N Cystic structure
- Y / N Solid mass
- Y / N Complex mass



Comments: _____

Comments: _____

Hank Hall, R.D.M.S., R.V.T., R.D.C.S.

Physician